



**PATIENT**

Penny Paden

**SPECIES**

Feline

**BREED**

DSH

**SEX**

Female Spayed

**AGE**

15 months

**WEIGHT**

11.9lbs

**INTERPRETED BY**

Maggie Machen Lamy,  
DVM, DACVIM  
(Cardiology)

**IMAGING PERFORMED BY**

Sands Hill Mobile  
Veterinary Ultrasound

**HOSPITAL NAME**

Pine Valley Animal  
Hospital

**REFERRING VET**

Dr. Tarter

**INVOICE**

28690

**DATE**

2/1/23

**PRESENTING CLINICAL SIGNS**

History: Grade 3/6 heart murmur. Asymptomatic.

**ECHOCARDIOGRAM FINDINGS**

2D, m-mode, color flow and doppler imaging is available. The left ventricular wall is normal in dimension. There is a normal endocardium. The left atrium is high normal. Mild MV thickening with mild eccentric mitral regurgitation. No obvious systolic anterior motion of the MV is seen. The right atrium is normal in size. The right ventricle appears normal. No TR. Blood flow through both the LVOT and RVOT are normal in velocity. No obvious congenital shunts. No effusions or cardiac tumors are identified.

**CARDIAC CHART**

FELINE CARDIAC PARAMETERS	BODY WEIGHT (kg)	HR (BPM)	IVSd (cm) (Moise, Pipers)	LVIDd (cm) (Moise, Pipers)	LWVd (cm) (Moise, Pipers)	FS (%)	EF (%)
NORMAL PARAMETER	-----	150-240	0.35-0.55	<2 (mean 1.5)	3.5-0.55	35-67	80-100
PATIENT	5.4	230	0.43	1.3	0.46	58	90
FELINE CARDIAC PARAMETERS	LA/AO (Boon)	LA/AO HEART BASE (Swe) (Abbott)	LA 2D short axis Base view (cm) (Abbott)		LVOT VEL (m/s)	RVOT VEL (m/s)	E max (m/s)
NORMAL	<1.5	<1.3	<1.2		<1.6	<1.3	<0.9
PATIENT	1.5	1.2	1.0		1.2	0.9	NM

*\*Note: All measurements based upon multi-modal images and methods. An average value is reported.*  
 Adapted from June Boon, Veterinary Echocardiography, 1998  
 Abbott J & MacLean H JVIM 2006;20: 111-119, Moise et al. Am J Vet Res 47:1476, 1986. Pipers et al. Am J Vet Res 40:882, 1979.

**INTERPRETATION OF THE FINDINGS & FURTHER RECOMMENDATIONS**

The only cause of a murmur is mild mitral regurgitation. MR in kittens is typically due to either MV dysplasia (abnormal morphology from birth) or secondary to abnormal valve motion (SAM/HOCM); the former is suspected. The degree of disease is mild with a normal left atrial dimension, indicating the risk of complication is low. It is important to note that small defects are easily missed, particularly in young kittens and referral should always be considered in any congenital cases. That being said, suspicion is low in this case.

Given these findings, no medications are indicated as risk for complication is currently low. Monitor of any signs of progressive cardiac disease including breathing changes or signs of a blood clot event.

The risk for general anesthesia is low, however heart rate stimulating drugs such as atropine, glycopyrrolate should be avoided unless medically necessary. Even without significant pathology, there is an elevated risk for fluid overload in this patient. Judicious IV fluid use is recommended.



**PATIENT**

Penny Paden

**SPECIES**

Feline

**BREED**

DSH

**SEX**

Female Spayed

**AGE**

15 months

**WEIGHT**

11.9lbs

**INTERPRETED BY**

Maggie Machen Lamy,  
DVM, DACVIM  
(Cardiology)

**IMAGING PERFORMED BY**

Sands Hill Mobile  
Veterinary Ultrasound

**HOSPITAL NAME**

Pine Valley Animal  
Hospital

**REFERRING VET**

Dr. Tarter

**INVOICE**

28690

**DATE**

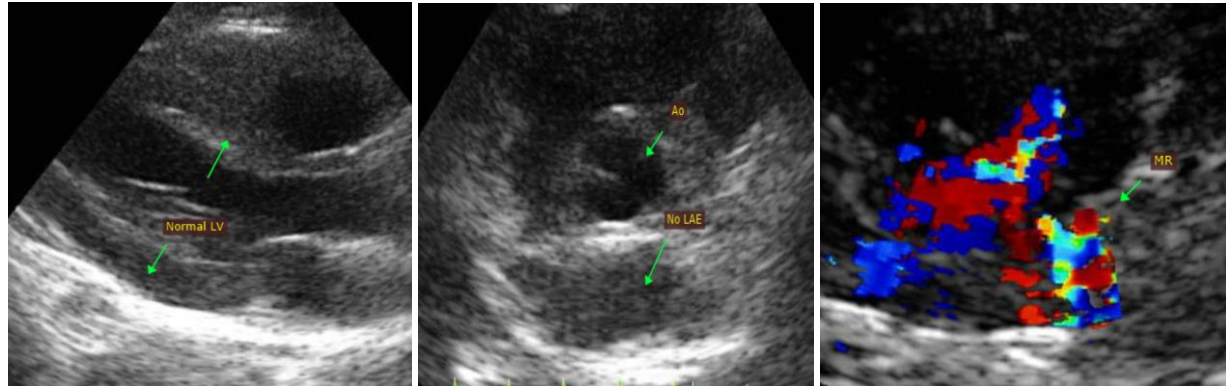
2/1/23

**PLAN**

Consider referral in any congenital case.

If declined and assuming the murmur persists, a recheck echocardiogram is recommended in 6 months, sooner if development of any clinical signs.

**IMAGES**



The information and recommendations provided are based on the images presented by the referring veterinarian. No evaluation can be communicated regarding pathology that was not visible in the image/video clips provided.

Thank you for this referral. This report was generated using transcription software, and minor dictation errors may be present. If the clinical or image interpretation does not parallel your findings or if I can be of any further assistance, please contact me.

Maggie Machen Lamy, DVM  
Diplomate of the American College of Veterinary Internal Medicine (Cardiology)  
info@sonopath.com